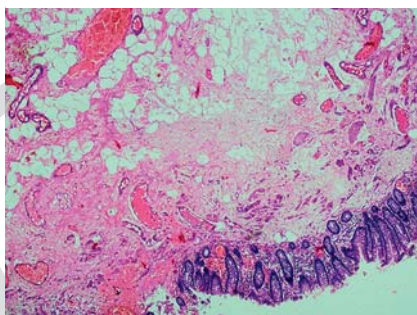


Endoscopic resection of a giant pedunculated lipoma arising from the ileocecal valve and causing ileocolic intussusception

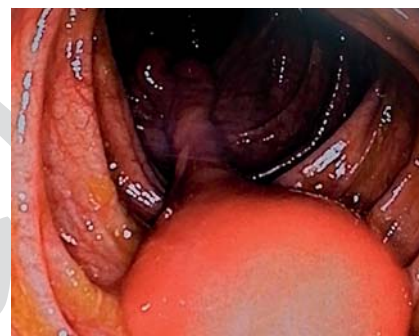
Lipomas are rare, nonepithelial, benign tumors representing 5% of all gastrointestinal tumors. They are the third most common benign mass in the colon. Colonic lipomas are sessile and infrequently pedunculated. The development of symptoms correlates with their size, with 75% of lipomas with a diameter of >4 cm being symptomatic [1, 2].

Treatment of large ileocolic lipomas with colonoscopic resection, however, is undefined. Pedunculated lipomas up to 11 cm have been removed via snare polypectomy without perforation [3]. Surgery is preferable when giant lipomas (diameter >4 cm) are complicated by intussusception, bowel obstruction, are sessile, or the serosa/muscularis propria extends into the stalk of the pedunculated lipoma [4].

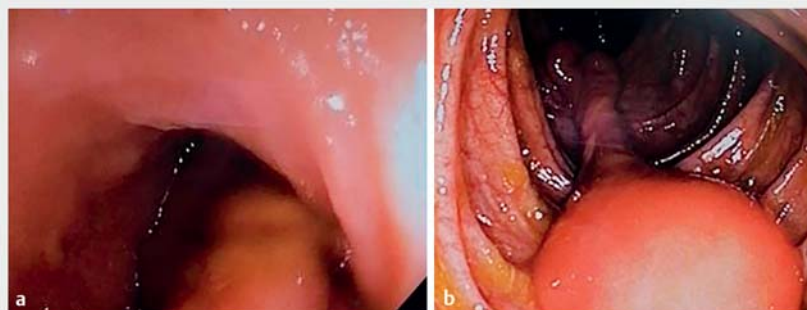
A 71-year-old woman was referred to our institution for removal of a large (diameter 6 cm) pedunculated lipoma, histologically documented (► Fig. 1) and arising from the ileocecal valve (► Fig. 2). She had experienced intermittent, crampy, right-abdominal pain for 5 months. During colonoscopy, intussusception of the lipoma into the terminal ileum or into the cecum was observed (► Fig. 3). On endoscopic ultrasonography, the lipoma appeared as a hyperechoic lesion with regular borders in the three layers, without extension of the muscularis propria into the pedicle. The stalk had a diameter of 1.5 cm and length of 2.5 cm. On consideration of our findings, together with suggestions from other authors in the literature [2–4], we decided to proceed with endoscopic resection of the lipoma. Successful snare polypectomy was performed after endolooping the base of the stalk (► Fig. 4, ► Video 1). Post-polypectomy bleeding (oozing) was stopped by clipping (► Fig. 5). Using only endoscopic ligation of the lipoma (loop-and-let-go) was not selected because of the possible transformation into liposarcoma. Therefore, the entire tumor was



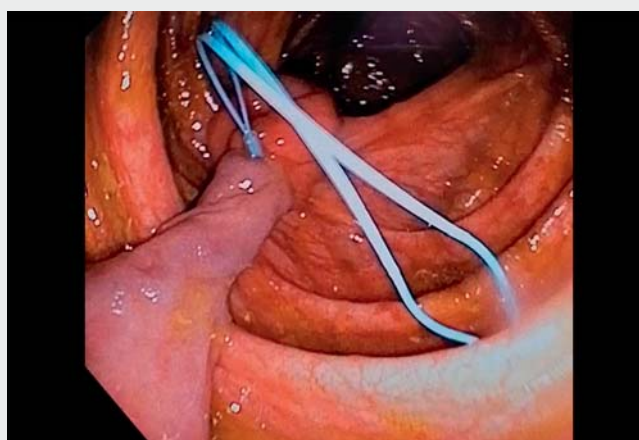
► Fig. 1 Fat cells proliferating in the submucosal layer.



► Fig. 2 Large (diameter 6 cm) pedunculated lipoma arising from the ileocecal valve.

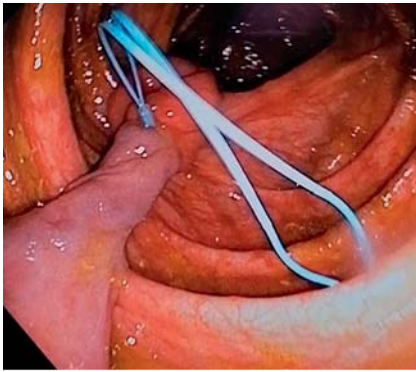


► Fig. 3 During colonoscopy, intussusception of the lipoma into the terminal ileum (left) or into the cecum (right) was observed.

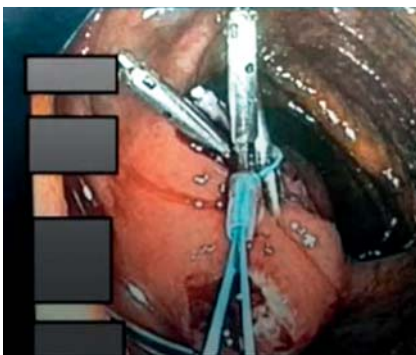


► Video 1 Endoscopic resection of a giant pedunculated lipoma.





► **Fig. 4** Endoloop ligation of the base of the stalk.



► **Fig. 5** Post-polypectomy bleeding (oozing) was stopped by endoloop ligation and clipping.

sent for histopathologic examination [5]. The patient was discharged from the hospital the next day in good condition. New histopathologic examination of the tumor revealed fat cells proliferating in the submucosal layer. To conclude, symptomatic, large, benign, pedunculated, ileocolic lipomas, without extension of serosa/muscularis propria into the stalk, could be safely resected endoscopically.

Endoscopy_UCTN_Code_TTT_1AQ_2AD

Competing interests

The authors declare that they have no conflict of interest.

The author

Panagiotis Kasapidis

Department of Gastroenterology and Endoscopy Unit, Central Clinic of Athens, Athens, Greece

Corresponding author

Panagiotis Kasapidis, MD, PhD, AGAF, FEBGH

Department of Gastroenterology and Endoscopy Unit, Central Clinic of Athens, Asklipiou 31, 10680, Athens, Greece
kasapendo@yahoo.gr

References

- [1] Casiraghi T, Masetto A, Beltramo M et al. Intestinal obstruction caused by ileocolic and colocolic intussusception in an adult patient with cecal lipoma. *Case Rep Surg* 2016; 2016: 3519606
- [2] Hu CC, Chien RN, Lin CL et al. Giant colonic lipoma arising from the ileocecal valve and causing cecal-transverse colonic intussusception. *Advances in Digestive Medicine* 2016; 3: 191–194
- [3] Chehade H, Zbibo RH, Nasreddine W et al. Large ileocecal submucosal lipoma presenting as hematochezia, a case report and review the literature. *Int J Surg Case Rep* 2015; 10: 1–4
- [4] Park N, Kuk C, Shin E et al. Ileocolic intussusception caused by giant submucosal colonic lipoma: a rare case report. *Int J Surg Case Rep* 2022; 97: 107451
- [5] Ivekovic H, Rustemovic N, Brkic T et al. Endoscopic ligation (“loop-and-let-go”) is effective treatment for large colonic lipomas: a prospective validation study. *BMC Gastroenterol* 2014; 14: 122

Bibliography

Endoscopy 2023; 55: E501–E502

DOI 10.1055/a-2032-3418

ISSN 0013-726X

© 2023. The Author(s).

This is an open access article published by Thieme under the terms of the Creative Commons Attribution-NonDerivative-NonCommercial License, permitting copying and reproduction so long as the original work is given appropriate credit. Contents may not be used for commercial purposes, or adapted, remixed, transformed or built upon. (<https://creativecommons.org/licenses/by-nc-nd/4.0/>)

Georg Thieme Verlag KG, Rüdigerstraße 14, 70469 Stuttgart, Germany



ENDOSCOPY E-VIDEOS

<https://eref.thieme.de/e-videos>



Endoscopy E-Videos is an open access online section, reporting on interesting cases and new techniques in gastroenterological endoscopy. All papers include a high quality video and all contributions are freely accessible online. Processing charges apply, discounts and waivers acc. to HINARI are available.

This section has its own submission website at <https://mc.manuscriptcentral.com/e-videos>